10.2.2

The Retina, Retinopathies, and Retinal Detachment

The Retina

The **retina** is a complex structure containing specialized cells that are capable of converting light into electrochemical signals (action potentials) that are then transmitted to the brain to give us sight. The retina is made up of two main layers: the neural layer and the pigmented layer.

The **neural layer** is made of three layers of neurons: the ganglion cells, bipolar neurons, and the photoreceptors. As light passes into the retina, it will first encounter blood vessels, then ganglion cells, then bipolar cells, and then stimulate the photoreceptor cells (rods and cones). The resulting electrical signals are then transmitted via the bipolar neurons and ganglion cells out of the eye and to the visual cortex of the brain.

The **pigmented layer** is located behind the photoreceptors and is made of pigmented epithelial cells (dark in color) that function to absorb scattered light. This prevents light from reflecting within the eye and stimulating photoreceptor cells inappropriately. The pigmented epithelium has tight junctions between the cells and thus creates a barrier between the choroid blood supply and the rest of the retinal cells. As a result, the pigmented epithelium becomes a selective membrane that regulates what is transported to the photoreceptors. Retinal pigment epithelium also helps recycle 11-trans retinal back to the photosensitive 11-cis retinal form to be used again in the process of phototransduction.

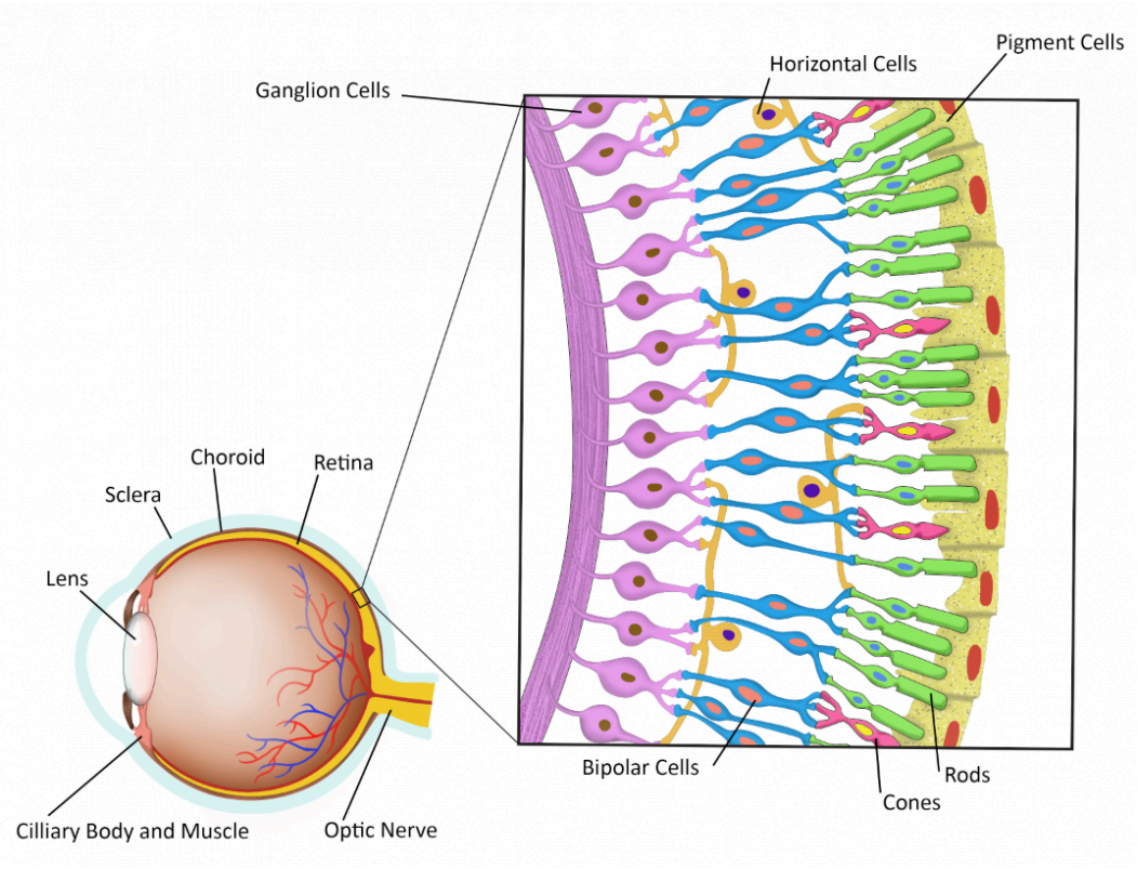

Structures of Eye and Retina *Image by Becky T. BYU-I W20.*

The fundus is the interior surface of the eye past the lens that includes the retina, optic disk, macula lutea, and fovea centralis. The **optic disc** is also known as the optic nerve head and is the area where the ganglion cell axons exit the eye as the optic nerve. The **macula lutea** is where light focuses to give us our central vision. The **fovea centralis** is an area within the macula that contains only cones and is responsible for our sharpest vision. In a fundoscopic exam, the optic disc is located closer to the nose (nasal) compared to the macula and fovea centralis, which are located in the darkened circular area in the center. This means that when performing a fundoscopic exam or viewing photographs of the fundus, you can tell if it's a right eye or left eye based on where the optic nerve is located (assume anatomical position).

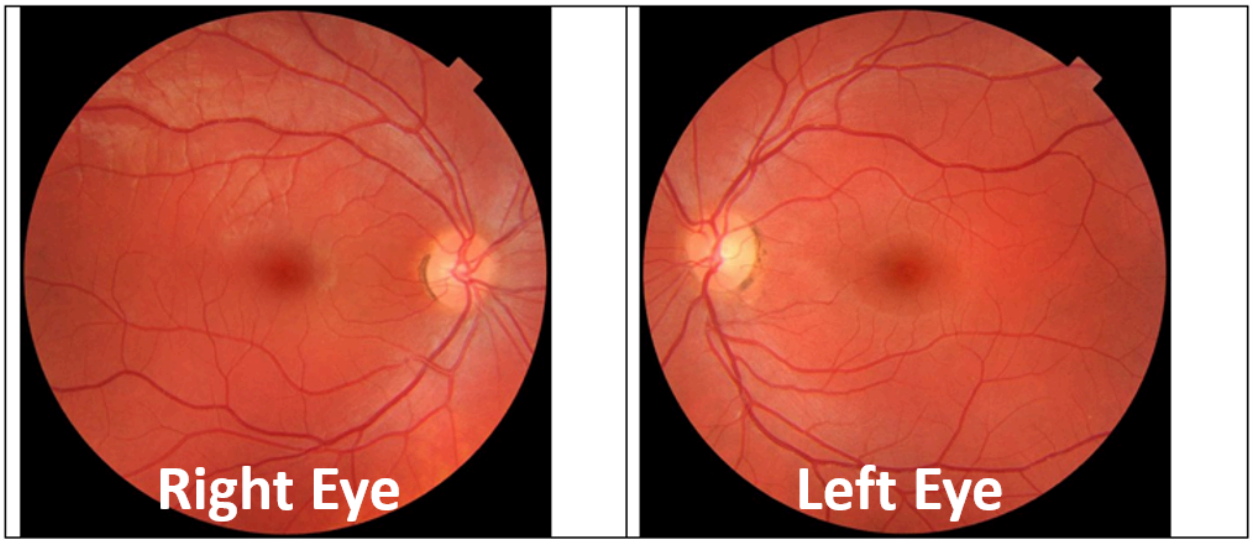

https://commons.wikimedia.org/wiki/File:Fundus_photograph_of_normal_right_eye.jpg; Public Domain.
This is a picture of the fundus of a normal right eye and a normal left eye. The optic disks are the lighter circles towards the center of the page with vessels radiating away from them. The macula lutea is the dark region in the middle of each fundus and its center contains the fovea centralis.

Retinopathy

Retinopathy is a disease of the retina that can lead to vision impairment or vision loss. Retinopathy is due to blood vessels in the back of the eye becoming damaged. The network of capillaries within the eyes are critical for proper retina function and quite intricate. Note in the image below that there are both retinal capillary networks (capillaries on or within the neural layer) as well as choriocapillaris that provide blood deep to the retinal pigment epithelium. This damage is usually due to high blood pressure and/or sustained high blood glucose levels. There is very little pain with retinopathy and in many cases, medical help is not sought out until symptoms are bad enough to cause vision changes. However, early detection of retinopathy leads to a much better prognosis.

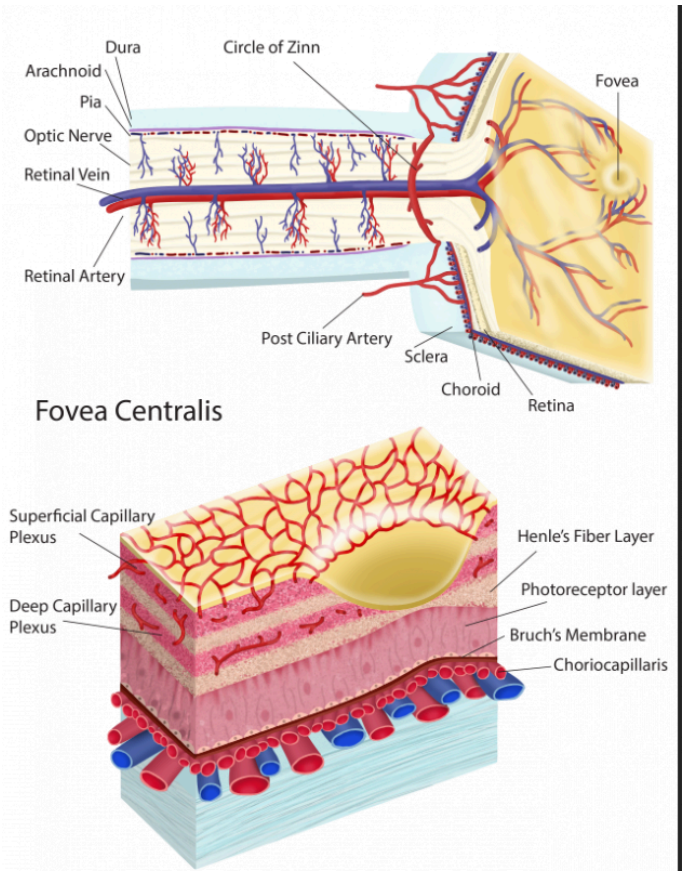

Vascular Networks of the Eye *Image by Becky T. BYU-I W20*

Retinopathy involves neurovascular changes that include microaneurysms, neovascularization, hemorrhages, and opacities. Microaneurysms (bulging out of a capillary wall) often result from damaged **pericytes**, which are contractile cells just outside the capillary endothelium that give the capillaries extra structural support. If pericytes get damaged, the capillary wall is weakened which potentiates microaneurysm formation. **Neovascularization** occurs when the retinal cells are not getting enough oxygen. When this happens, the hypoxic cells will release vascular endothelial growth factor (VEGF), which causes the growth of new vessels towards the cells that are hypoxic. This is the body's way of trying to maintain blood flow and oxygen to cells. It sounds promising, but the new vessels are not strong and tend to be weakly supported by pericytes. These new vessels damage easily and the resulting retinal hemorrhage can further damage retinal cells and also lead to the formation of opacities. **Opacities** are dark or cloudy areas on the retina that can be caused by bleeding, tissue proliferation, exudates, edema, and cotton wool spots. **Cotton wool spots** are an abnormal finding on a fundoscopic exam and appear as fluffy, white patches on the retina. They are caused by damage

to the nerve fibers and are the result of the accumulation of axoplasmic (cytoplasm within the axon of a nerve) material within the nerve fiber layer.

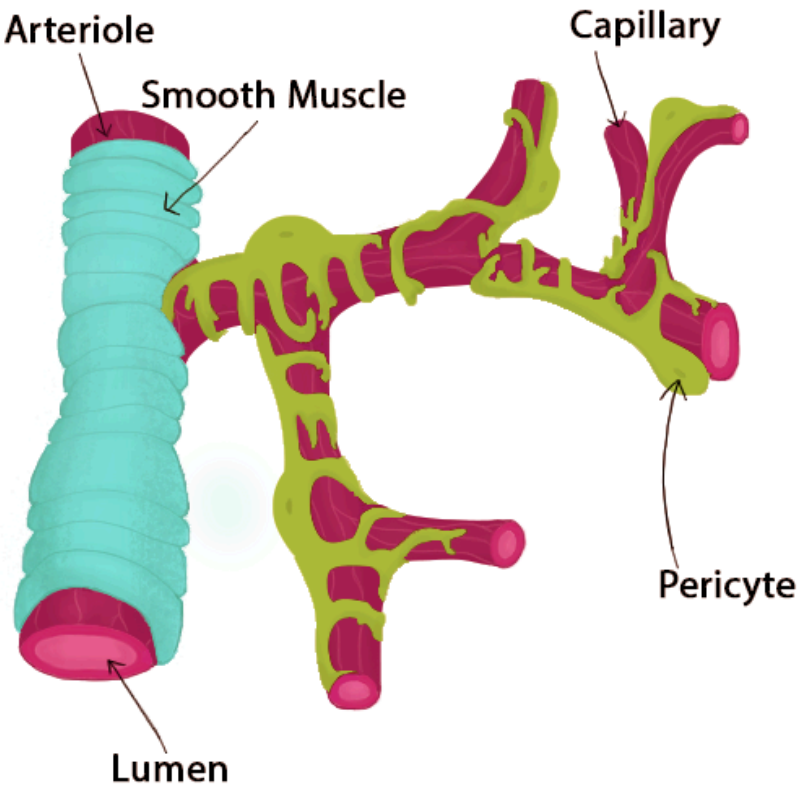

Image by Alexa C. BYU-I W20

Diabetic Retinopathy

The most common type of retinopathy is **diabetic retinopathy**. Diabetic retinopathy is a complication of diabetes where sustained high blood glucose levels eventually lead to damage of the retina. Diabetic retinopathy can be divided into two types: proliferative and non-proliferative.

Non-proliferative diabetic retinopathy occurs when high blood sugar leads to a dysregulation of ocular blood flow. The mechanism by which this happens is two-fold: First, excess glucose can find its way to the basement membrane of the tiny capillaries in the retina and cause them to thicken due to the accumulation of water. As the capillary basement membrane thickens, it can disrupt the intimate association of pericytes. Some pericytes may be removed or even die. This will lead to a weakened area on the capillary that may result in a microaneurysm as pressure pushes against the weakened wall. Second, excessive blood glucose over time is particularly dangerous because it leads to the production of **advanced glycation end products (AGEs)** which are plasma and endothelial proteins that become irreversibly glycated in a non-enzymatic fashion (i.e. simply due to chronic hyperglycemia). Glycated hemoglobin (called HbA1c) is a common clinical measurement to assess average blood glucose levels over the past two weeks. AGE formation can inactivate important proteins like glycated eNOS which helps maintain healthy circulation and blood pressure within the delicate retinal capillaries. AGEs bind to receptors (appropriately named 'RAGEs') and induce cellular stress, endothelial cell damage, and hypercoagulability (RAGEs are expressed on platelets). Collectively, chronic hyperglycemia leads to increased blood pressure, damaged endothelial cells and pericytes, and potentially thrombus/embolus formation.

High blood sugar is also associated with poor lipid profiles. Hyperlipidemia is known to also cause vessel damage. The combined effect of basement membrane thickening, disruption of endothelial cell signaling, endothelial cell damage, and bulging of weakened walls cause a reduction of healthy blood circulation through the retina. Nerve cells may

become ischemic which deprives them of the oxygen and nutrients required to maintain axonal flow. This leads to the formation of cotton wool spots. Edema (another type of opacity) may also be seen as damaged capillaries lose plasma proteins, thus increasing the interstitial osmotic pressure (ICOP) and decreasing the blood osmotic pressure (BCOP).

Proliferative diabetic retinopathy is more severe and generally follows non-proliferative diabetic retinopathy. Proliferative diabetic retinopathy is characterized by an expansion of newly formed blood vessels that are fragile and easily damaged. This neovascularization can affect vision in a couple of ways. First, the new blood vessels may bleed into the vitreous humor and cloud the vision. Second, the new blood vessels, although weak, anchor tightly to the retina. Then, normal movement of the thick vitreous humor may be enough to pull on the retina and create a retinal detachment (separation of the neural sensory layer from the pigmented epithelial layer).

Patients with diabetes should have annual eye exams to check for symptoms of retinopathy. The best approach to prevent the progression of diabetic retinopathy and to preserve vision is to control blood glucose levels, hypertension, and hyperlipidemia. Other treatment methods include laser photocoagulation, intravitreal injections of anti-VEGF agents (to limit the amount of exudate and decrease neovascularization), and vitrectomy to remove vitreous hemorrhage and vitreoretinal membranes. **Retinal photocoagulation** is a technique where laser light energy is used to give a thermo burn to the retina. The laser is carefully directed to avoid the macula and fovea and targets the peripheral areas instead. These burns will destroy newly forming blood vessels as well as retinal cells. The result is that neovascularization will be stopped in the areas treated. Since the retinal cells are destroyed as well, much of the VEGF stimulus will be reduced which will minimize future neovascularization.

Retinal Detachment

Retinal detachment is the separation of the neural retinal layer from the pigmented epithelium. Retinal detachment is considered a medical emergency because the blood supply to the retina is cut off. Most of the retina receives its blood from the choriocapillaris of the choroid and the central retinal artery. The fovea centralis only receives blood from the choriocapillaris, so retinal detachment at the fovea centralis can cause irreversible vision loss due to lack of blood supply leading to tissue death.

Common risk factors of retinal detachment include advancing age, moderate or severe myopia, diabetic retinopathy, and previous intraocular surgery. Common symptoms and manifestations of retinal detachment include painless changes in vision (flashing lights or sparks), floaters, and a black curtain starting in the periphery. Common treatments include a vitrectomy to remove the vitreous liquid or laser therapy to seal retinal tears.

There are three types of retinal detachment:

- **Rhegmatogenous detachment:** This is the most common type of detachment and involves a tear or hole in the retina (“rhegma” means tear). The tear allows an accumulation of liquefied vitreous to seep underneath the neurosensory retina and lead to its separation from the pigmented layer. It is more common in older adults and people with extreme myopia (nearsightedness). Severe myopia often involves a longer anterior/posterior axis of the eye. This eye shape may cause the retina to tear more easily.
- **Traction detachment:** This is the second most common type of detachment and is due to mechanical forces on the retina. Remember that the vitreous humor is dense and thick, therefore movement of this fluid can exert a frictional force on the retina. These mechanical forces may be due to sudden head trauma or more subtle movements as in the case of proliferative diabetic retinopathy. Another common cause of traction detachment occurs during a cataract surgery where pulling and tugging on the defective lens agitates the vitreous humor in such a way that the retina becomes pulled from the pigmented epithelium.
- **Exudative detachment:** This detachment occurs when an accumulation of fluid develops under the neurosensory retina without the presence of a tear. This can happen in instances of severe hypertension, ocular inflammatory responses, or neoplasm effusions.